eOftalmo

DISCUSSED CLINICAL CASES

Mixed retinal vascular occlusion as the first manifestation of antiphospholipid antibody syndrome: case report of an infrequent presentation

Oclusão vascular retiniana mista como primeira manifestação da síndrome do anticorpo antifosfolipídeo – uma apresentação infrequente: relato de caso

Letícia Oliveira Audi[1], Renato Bredariol Pereira[1], Moisés Moura de Lucena[1], Rodrigo Jorge[2], Francyne Veiga Reis Cirino[1]

1. Setor de Retina Clínica e Cirúrgica, Hospital das Clínicas de Ribeirão Preto, Faculdade de Medicina de Ribeirão Preto, Universidade de São Paulo, Ribeirão Preto, SP, Brazil.
2. Departamento de Oftalmologia, Faculdade de Medicina de Ribeirão Preto, Universidade de São Paulo, Ribeirão Preto, SP, Brazil.

KEYWORDS:

Central retinal artery occlusion; Central retinal vein occlusion; Vascular occlusions; Antiphospholipid antibody syndrome.

ABSTRACT

Simultaneous occlusion of the central retinal vein and artery is rarely observed in cases of retinal vascular disorders. It usually presents as a sudden and painless loss of vision, and its outcome can be devastating if not treated in time. The association between thrombotic events and antiphospholipid antibody syndrome is well established; however, the onset of antiphospholipid antibody syndrome with ophthalmic manifestations is rare. Herein, we present the case of a 66-year-old woman with antiphospholipid antibody syndrome whose first manifestation was mixed arteriovenous occlusion of the retina.

PALAVRAS-CHAVE:

Oclusão de artéria central da retina; Oclusão de veia central da retina; Oclusões vasculares; Síndrome do anticorpo antifosfolípide.

RESUMO

A oclusão simultânea de veia e de artéria central da retina é raramente observada entre as desordens vasculares retinianas. Quando ocorre, apresenta-se como perda súbita e indolor da visão e seu desfecho é devastador caso não tratada em tempo hábil. A associação entre eventos trombóticos e a síndrome do anticorpo antifosfolípide é bem estabelecida, mas a abertura do quadro de síndrome do anticorpo antifosfolípide com manifestação oftalmológica é incomum. Neste trabalho, apresentamos um caso de síndrome do anticorpo antifosfolípide cuja primeira manifestação foi a oclusão mista, arteriovenosa, da retina.

Corresponding author: Leticia de Oliveira Audi. E-mail: leticia.audi@gmail.com
Received on: May 26, 2023. **Accepted on:** Sept 11, 2023.
Funding: No specific financial support was available for this study. **Conflict of interest:** None of the authors have any potential conflict of interest to disclose.
Approved by the following Research Ethics Committee: Hospital das Clínicas da Faculdade de Medicina de Ribeirão Preto da USP – HCFMRP/USP (CAAE: 69270223.8.0000.5440)

How to cite: Audi LO, Pereira RB, Lucena MM, Jorge R, Cirino FV. Mixed retinal vascular occlusion as the first manifestation of antiphospholipid antibody syndrome: case report of an infrequent presentation. eOftalmo. 2023;9(3):xx-xx.

DOI: 10.17545/eOftalmo/2023.00XX

This content is licensed under a Creative Commons Attribution 4.0 International License.

INTRODUCTION

Antiphospholipid antibody syndrome (APS) is a systemic autoimmune disease associated with significant morbidity and mortality. It is characterized by venous or arterial thrombotic events that are often associated with gestational complications and recurrent fetal morbidity as well as the presence of high and persistent levels of antiphospholipid antibodies, such as lupus anticoagulant, anticardiolipin, and anti-β2 glycoprotein-1 antibodies[1].

The prevalence of APS is estimated to be 40-50 cases per 100,000 people[2], which makes APS the leading cause of acquired thrombophilia. The presence of antiphospholipid antibodies induces a prothrombotic state, whose clinical manifestation varies depending on the affected vascular region[3]. In addition to gestational complications, other clinical manifestations such as cardiopulmonary, abdominal, skin, osteoarticular, hematological, renal, neurological, and ophthalmological impairment are observed.

APS can occur either on its own (primary form) or in association with other autoimmune diseases (secondary form). In the secondary form, APS mainly occurs in association with systemic lupus erythematosus (SLE), preferentially affecting young women of reproductive age. However, recent studies have revealed delayed diagnoses of this clinical condition in patients aged >50 years.

A North American study involving patients with APS demonstrated an increase in the median age at diagnosis, which was estimated to be 55–64 years in men and >75 years in women[4]. In Korea, the average age of incidence was high in men (70-79 years), whereas that in women was bimodal (30-39 and 70-79 years)[5]. Another study at a university hospital in Tunisia showed an 11% increase in APS incidence in older patients, who accounted for 7 of the 62 examined patients. Of these, 5 were women, with the mean age of 77 ± 6 years, all of whom had experienced a vascular thrombotic event[6]. Notably, none of these three previous studies have described ophthalmic involvement in retinal vascular thrombosis events.

Retinal vascular diseases cause a sudden and painless loss of visual acuity (VA), leading to devastating results if not treated in time[7]. Thrombosis of the central retinal artery is a clinical manifestation that is observed in 1.5% of patients with APS[8]. However, mixed retinal vascular occlusion involving the central retinal artery and vein is a rare event, with the involvement of multiple pathological mechanisms[9,10]. Several risk factors are associated with venous occlusions, especially systemic arterial hypertension, arteriosclerosis, diabetes mellitus, and thrombophilia[11]. Inflammatory causes, compression, and vasospasm are the predisposing factors that can cause damage to adjacent arteries along with vascular occlusion[12].

There are a few reports of retinal arteriovenous occlusions in the literature. These occlusions are described as rare events and are related to events secondary to SLE, orbital pseudotumor, Behçet's disease, posterior scleritis, ocular trauma, leukemia, and cardiovascular events[13–15]. It is believed that arterial occlusion is secondary to venous occlusion because venous occlusion leads to an increase in the blood pressure inside the vessels, which is then transmitted to the arteries, with a consequent reduction or interruption of the blood flow in the arterial bed[16].

Herein, we present the case of a patient with mixed occlusion of the central retinal artery and vein who had no previous history of thrombophilia and was diagnosed with APS due to her ocular condition. This report aimed to emphasize the importance of etiological investigation in similar cases.

CASE REPORT

A 66-year-old woman was admitted to the emergency department with the chief complaint of a sudden and painless loss of VA in the right eye (OD) associated with a 3-day holocranial headache. She had no ophthalmic history but had a history of poorly controlled hypertension; however, on the day of admission and during her follow-up visits, her blood pressure level remained approximately 120/90mmHg. When actively questioned, she reported an episode of "swelling" in her right lower limb that occurred >20 years ago, with brief hospitalization for treatment and no medication history after hospitalization.

Upon ophthalmologic evaluation, she had VA of hand movement (HM) in the right eye, with no improvement after correction, as well as 20/20 in the left eye (OS), with refraction of +3.0 sph, −1.00 cyl at 70º. Biomicroscopy of both eyes revealed calm eyes, transparent cornea, well-formed anterior chamber, no cells, trophic iris, nuclear cataract 2/4+, and intraocular pressure (IOP) levels of 12mmHg in OD and 14mmHg in OS.

Fundoscopy on the day of admission showed a transparent vitreous without cells in OD, an optic nerve with ill-defined borders, arterial thinning with mild retinal pallor, venous engorgement in the tem-

poral arcades, macular edema, candle-flame hemorrhages in all four quadrants, and superior nasal preretinal hemorrhage (Figure 1A). In OS, the vitreous was clear and the optic nerve showed no changes, but increased vascular tortuosity and small intraretinal hemorrhages were noted in the inferior temporal arcade and temporal to the macula (Figure 1B). Optical coherence tomography was performed on the day of assessment (Figure 2).

Considering the diagnosis of occlusion of the central retinal artery and vein in OD and suspicion of APS, hematological assessment was requested for

Figure 1. (A): Fundus photograph showing combined central retinal vein and artery occlusion in the right eye. (B) Retinography of the left eye showing increased vascular tortuosity and intraretinal hemorrhages.

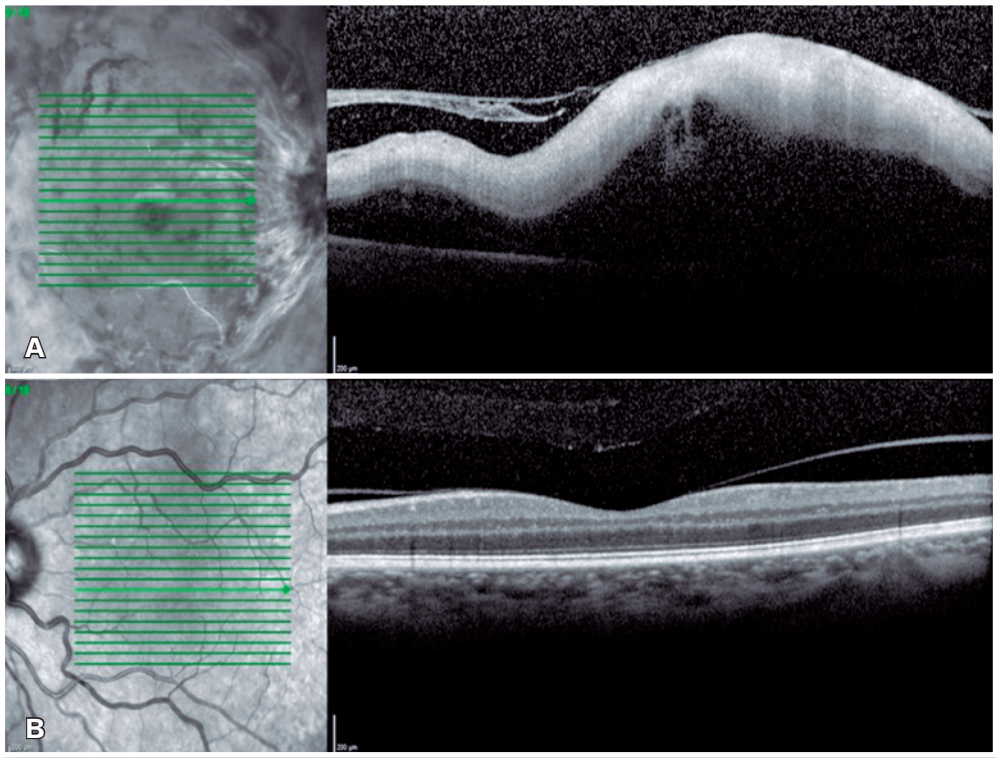

Figure 2. Optical coherence tomography. (A) Right eye: thickened and partially detached posterior hyaloid membrane showing subtle points suggestive of sub-hyaloid hemorrhage, significant disorganization, and edema of the inner layers of the retina. (B) Left eye: partial detachment of the posterior hyaloid membrane, with normal inner and outer layers and choroid.

systemic investigation, and treatment was administered with three monthly intravitreal applications of bevacizumab in OD. Due to the presence of extensive intraretinal hemorrhage, laser panphotocoagulation was not indicated initially.

Laboratory tests revealed the following results: D-dimer level, 6.19 μg/mL (reference value <0.5 μg/mL); anticardiolipin antibody IgM level, 34.8 MPL (moderately positive); anti-β2 glycoprotein IgM level, >150 U/mL (positive), and absence of lupus anticoagulant. For diagnostic purposes, the tests were repeated after 21 weeks, which remained negative for lupus anticoagulant and revealed anti-β2 glycoprotein IgM level of 149.3U/mL (positive) and anticardiolipin antibody IgM level of 35.5 MPL (moderately positive).

These results confirmed the diagnosis of APS, and the patient was hospitalized for anticoagulation with enoxaparin and warfarin, under strict systemic control. The patient initially responded adequately to treatment, with subsequent transition to oral anticoagulation. However, after 3 months, she presented with VA of HM in OD and 20/25 in OS, with IOP levels of 32mmHg in OD and 17mmHg in OS. OD biomicroscopy revealed the presence of rubeosis iridis at 09:00 and 12:00, and retinal mapping showed pale optic nerve and retina, with ghost vessels in all four quadrants (Figure 3).

Treatment for neovascular glaucoma was initiated with hypotensive eye drops and laser photocoagulation; however, due to severe pain and significant corneal edema secondary to high intraocular pressure levels, the procedure could not be performed. The patient's condition progressed unfavorably until the absence of light perception.

DISCUSSION

The findings indicative of retinal arteriovenous occlusion are a sudden and painless unilateral loss of VA, retinal pallor with or without a cherry-red spot, retinal edema, intraretinal hemorrhages, and increased vascular tortuosity. In uncertain cases, fluorescein angiography may be helpful, revealing delayed arterial filling and a prolonged arteriovenous phase[10].

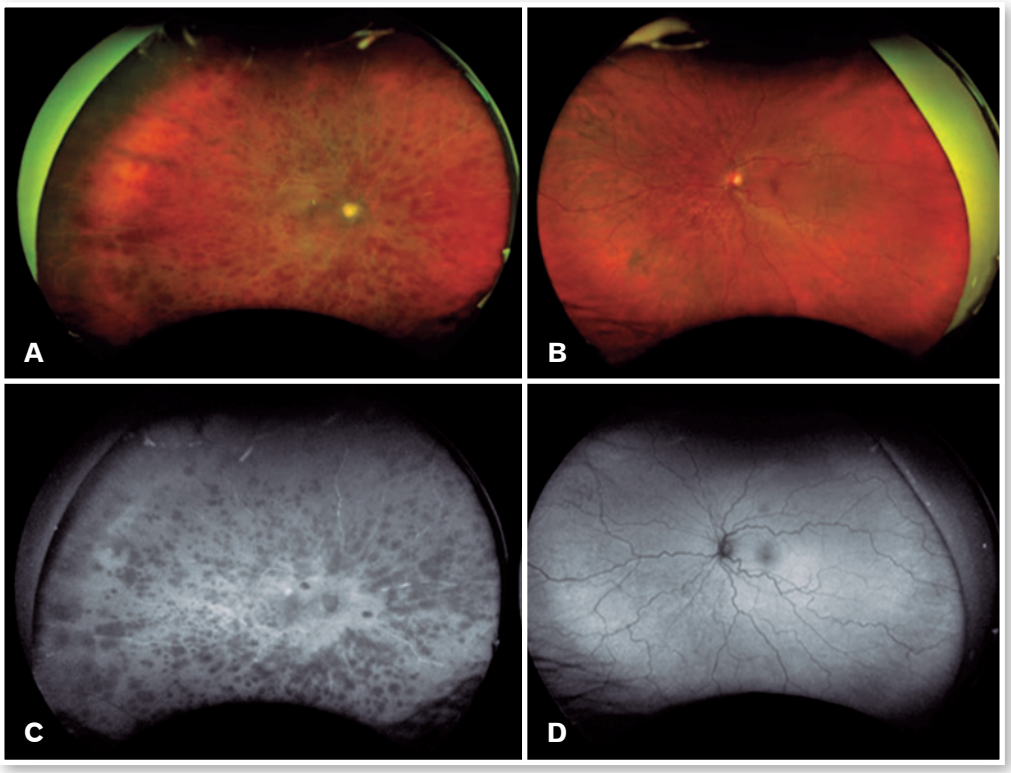

Figure 3. (A) Wide-angle retinography (3-month follow-up after obtaining results shown in Figure 1): Right eye (OD) with reduced intraretinal hemorrhages, pale optic nerve, and ghost vessels in all four quadrants. (B) Left eye (OE): increased vascular tortuosity. (C) OD autofluorescence: multiple areas of hypoautofluorescence in all four quadrants (retinal hemorrhages); presence of ghost vessels. (D). Left-eye autofluorescence: absence of pathological hypo/hyperautofluorescence.

The present clinical case showed unequivocal signs of both arterial and venous occlusions of retinal vessels, and fluorescein angiography was not performed at the request of the hematology team.

In ophthalmological practice, the occurrence of vascular occlusion may precede other systemic complications; therefore, the diagnosis of retinal vascular occlusion should be accompanied with an etiological investigation, considering the risk factors observed in most cases. In particular, retinal arterial occlusion should be considered an ophthalmic emergency, as it is systemically similar to myocardial infarction and stroke[17] and is considered an important risk factor for these comorbidities.

Although the association between retinal vascular occlusions and APS is well established, the occurrence of retinal arteriovenous occlusions in patients without a previous diagnosis of systemic disease is uncommon. Combo-Soriano et al. analyzed a group of 40 patients with retinal vascular occlusions without risk factors and attempted to establish a correlation between vascular occlusions and the presence of anticardiolipin antibodies. Among them, 22.5% of patients showed positive anticardiolipin antibodies upon laboratory investigation. However, three of them (13.3%) had previously presented with thrombotic conditions, thereby making the difference in anticardiolipin antibody positivity between the groups statistically nonsignificant ($p=0.2158$). It was therefore not possible to establish sufficient clinical evidence to request anticardiolipin antibody testing for all patients with retinal vascular occlusion without previous thrombosis[18–20].

In the present case, the main clinical suspicion was the infrequent presentation of low VA associated with mixed retinal arteriovenous occlusion in OD and a previous history of hospitalization for treatment of leg swelling at the age of <40 years. This led to a strong suspicion of APS as a diagnostic hypothesis despite the patient's age at the presently described episode. This highlights the importance of a well-collected clinical history and etiological investigation in conjunction with the rheumatology and hematology teams in cases of a clinical suspicion of APS in patients with retinal vascular occlusion.

Valle et al. showed a significant improvement in VA in 7 of 12 patients examined after treatment with fibrinolytic drugs in the acute phase, preferably within the first 72 h[21], when central retinal artery occlusion was present. Other measures, such as ocular massage and anterior chamber paracentesis, have been described, but they remain unsatisfactory in most cases[22]. However, the visual prognosis after retinal vascular occlusion, especially arterial occlusion, remains poor, with irreversible loss of VA in most cases[18].

In the present case, the outcome was unfavorable, progressing to retinal neovascularization and neovascular glaucoma, possibly related to the extensive area of retinal ischemia resulting from venous and arterial vascular occlusions, even after injection with antivascular endothelial growth factor (anti-VEGF) antibody. The phenomenon of "100-day glaucoma" can occur in approximately 4% of patients with mixed occlusions, especially in severe and extensive cases. The term "100-day" refers to the mean time at which this complication can develop after vascular occlusion, although this time can vary widely[23,24].

With regard to treatment, retinal laser photocoagulation and intravitreal therapy with corticosteroids or anti-VEGF are the first choice of treatment. Photocoagulation proved beneficial only for patients with greater than two clock hours of anterior segment neovascularization or any degree of angle neovascularization.

In cases showing macular edema secondary to the occlusive process, a previous study showed a favorable response with intravitreal triamcinolone therapy, dexamethasone slow-release implants, and intravitreal injections of anti-VEGF drugs, with both on-label (ranibizumab or aflibercept) and off-label (bevacizumab) use[25].

Thus, the occurrence of retinal vascular occlusions secondary to APS, whether venous, arterial, or mixed, can have an unfavorable clinical course despite appropriate clinical management and joint rheumatological follow-up. Controlling risk factors is crucial to avoid new episodes of vascular occlusion and prevent systemic complications of the disease.

Vascular occlusions have a severe impact on VA and are a cause of increased morbidity in the general population, as they are often associated with both systemic and ophthalmic disorders. Therefore, detailed investigation of risk factors and close monitoring of patients are necessary to treat and prevent complications that could significantly impair the patient's quality of life.

REFERENCES

1. Cervera, R. Antiphospholipid syndrome. Thromb Res. 2017 Mar; 151 Suppl 1:S43–S47.

2. Durcan L, Petri M. Epidemiology of the Antiphospholipid Syndrome. *In*: Cervera R, Espinosa, Khamashta MA (eds), Antiphospholipid syndrome in systemic autoimmune diseases, 2nd edition. Elsevier, Amsterdam, 2016; 17- 30
3. Heras CB, Gómez AP, Hajkhan AM, Rubio ER. Síndrome antifosfolípido. Medicine - Programa de Formación Médica Continuada Acreditado. 2021;13(31):1760-1768.
4. Duarte-García A, Pham MM, Crowson CS, Amin S, Moder KG, Pruthi RK, et al. The Epidemiology of Antiphospholipid Syndrome: A Population-Based Study. Arthritis Rheumatol. 2019;71(9):1545-1552. Erratum in: Arthritis Rheumatol. 2020 Apr;72(4):597.
5. Hwang JJ, Shin SH, Kim YJ, Oh YM, Lee SD, Kim YH, et al. Epidemiology of Antiphospholipid Syndrome in Korea: a Nationwide Population-based Study. J Korean Med Sci. 2020 Feb 10;35(5):e35.
6. Cherif Y, Jallouli M, Hriz H, Gouiaa R, Marzouk S, Snoussi M, et al. Late-onset primary antiphospholipid syndrome in the elderly: a report of seven cases. Int J Rheum Dis. 2015;18(1):103-7.
7. Chakravarthi MD, Chandramouleeswaran V, Ranganathan LN, Allimuthu N, Kannan V, Mariappan V. Combined central retinal artery occlusion and central retinal venous occlusion with bilateral carotid artery disease in apatient with protein C deficiency. Neurology Asia. 2019;24(2):185-188.
8. Cervera R, Piette JC, Font J, Khamashta MA, Shoenfeld Y, Camps MT, Jacobsen S, Lakos G, Tincani A, Kontopoulou-Griva I, Galeazzi M, Meroni PL, Derksen RHWM, de Groot PG, Gromnica-Ihle E, Baleva M, Mosca M, Bombardieri S, Houssiau F, Gris JC, Quéré I, Hachulla E, Vasconcelos C, Roch B, Fernández-Nebro A, Boffa MC, Hughes GRV, Ingelmo M; Euro-Phospholipid Project Group. Antiphospholipid syndrome: clinical and immunologic manifestations and patterns of disease expression in a cohort of 1,000 patients. Arthritis Rheum 2002;46(4):1019–27.
9. Raval V, Nayak S, Saldanha M, Jalali S, Pappuru RR, Narayanan R, et al. Combined retinal vascular occlusion: Demography, clinical features, visual outcome, systemic co-morbidities, and literature review. Indian J Ophthalmol. 2020;68(10):2136-2142.
10. Schmidt D. Comorbidities in combined retinal artery and vein occlusions. Eur J Med Res. 2013;18(1): 27.
11. Risk factors for branch retinal vein occlusion. The Eye Disease Case Control Study Group. Am J Ophthalmol. 1993;116(3):286-96.
12. 12. Yen YC, Weng SF, Chen HA, Lin YS. Risk of retinal vein occlusion in patients with systemic lupus erythematosus: a population-based cohort study. Br J Ophthalmol. 2013;97(9):1192-6.
13. Parchand SM, Vijitha VS, Misra DP. Combined central retinal artery and vein occlusion in lupus. BMJ Case Rep. 2017 Jan 10;2017:bcr2016218848.
14. Kahloun R, Jelliti B, Abroug N, Khairallah Ksiaa I, Zaouali S, Ben Yahia S, Khairallah M. [Combined central retinal artery occlusion and central retinal vein occlusion secondary to Behçet's disease]. J Fr Ophtalmol. 2016;39(7):e191-2.French.
15. Sánchez-Tocino H, García-Layana A, Salinas-Alamán A, Alcalde-Navarrete JM, Panizo-Santos A, Martínez-Monge R. Central retinal vascular occlusion by orbital pseudotumor. Retina. 2004; 24(3):455-8.
16. Wang H, Chang Y, Zhang F, Yang R, Yan S, Dong J, et al. Clinical Features of Combined Central Retinal Artery and Vein Occlusion. J Ophthalmol. 2019 Oct 9;2019:7202731.
17. Biousse V, Newman N. Retinal and optic nerve ischemia. Continuum (Minneap Minn). 2014 Aug;20(4 Neuro-ophthalmology): 838-56.
18. Recchia FM, Brown GC. Systemic disorders associated with retinal vascular occlusion. Curr Opin Ophthalmol. 2000:11(6):462–7.
19. 19. Cobo-Soriano R, Sanchez-Ramon S, Aparicio MJ, Teijeiro MA, Vidal P, Suárez-Leoz M, et al. Antiphospholipid antibodies and retinal thrombosis in patients without risk factors: a prospective case-control study. Am J Ophthalmol. 1999;128(6):725–32.
20. Williams GA, Sarrafizadeh R. Antiphospholipid antibodies and retinal thrombosis in patients without risk factors: a prospective case-control study. Am J Ophthalmol. 2000;130(4):538-9.
21. Vallée JN, Paques M, Aymard A, Massin P, Santiago PY, Adeleine P, et al. Combined central retinal arterial and venous obstruction: emergency ophthalmic arterial fibrinolysis. Radiology. 2002;223(2):351-9.
22. American Academy of Ophthalmology, 2020. Text Book. Retina and Vitreous. Pag 176.
23. Rodrigues GB, Abe RY, Zangalli C, Sodre SI, Donini FA, Costa DC, et al. Neovascular glaucoma: a review. Int J Retina Vitreous. 2016 Nov 14;2:26.
24. Bromeo AJ, Lerit SJ, Grulla-Quilendrino P, Sosuan GM, Leuenberger E. Combined central retinal artery and vein occlusion following trabeculectomy. GMS Ophthalmol Cases. 2022 Jun 28;12:Doc18.
25. Patel A, Nguyen C, Lu S. Central Retinal Vein Occlusion: A Review of Current Evidence-based Treatment Options. Middle East Afr J Ophthalmol. 2016 Jan-Mar;23(1):44-8.

AUTHORS INFORMATIONS

» **Leticia de Oliveira Audi**
http://lattes.cnpq.br/2723026577340576
https://orcid.org/0009-0005-9746-6601

» **Moisés Moura de Lucena**
http://lattes.cnpq.br/7926589222695327
https://orcid.org/0000-0002-4726-6856

» **Renato Bredariol Pereira**
http://lattes.cnpq.br/2008604374629230
https://orcid.org/0000-0003-2040-7468

» **Rodrigo Jorge**
http://lattes.cnpq.br/4045374522226547
https://orcid.org/0000-0002-2652-0720

» **Francyne Veiga Reis Cyrino**
http://lattes.cnpq.br/0720130883701897
https://orcid.org/0000-0002-1892-6210